

# Surgical treatment of cherry eye

*With timely treatment, practitioners can relieve discomfort and reduce the risk of serious ophthalmic conditions.*



By Ari Zabell,  
DVM

*Contributing Author*

**M**ost of us have seen canine patients with the characteristic red, swollen mass of tissue, visible at the medial canthus, that is referred to as cherry eye (*Figure 1*, page 35). Clients are sometimes unconcerned about the problem, thinking it is just another part of their Pet’s personality or a normal characteristic for the breed. “I know he isn’t much to look at,” they might tell you, “but I love him anyway.” However, even if clients aren’t worried about the cosmetic aspects of the problem, cherry eye—or third eyelid gland prolapse—is a health issue that can have serious long-term effects on a Pet’s ocular health and quality of life.

Normally, the gland of the third eyelid is held in place by a connective tissue attachment between the ventral third eyelid membrane and the periorbital tissues. However, some breeds are prone to weakness in this tissue; recent data have shown particularly high prevalence of third eyelid gland prolapse in Neapolitan Mastiffs, American Cocker Spaniels, Lhasa Apsos and brachy-

cephalic breeds such as Bulldogs and Shih-Tzus (see *Eyelid disease: All dogs are not equal*, page 16). In particular, brachycephalic breeds have a genetically determined eye and lid structure that may require stronger connective tissue to hold the gland in place within the eyelid. In these dogs, any inflammation of the conjunctiva can cause retraction of the globe, which forces the lid and gland out of the orbit and often into a state of prolapse.

When the gland is no longer protected by the warm, moist environment behind the third eyelid, it is exposed to environmental elements such as wind, dirt and dust that can abrade and desiccate the third eyelid gland. This results in a secondary inflammation of the gland and conjunctival tissue. In response to the inflammation, the gland begins to hypertrophy. In most cases, this abnormal swelling and thickening prevent the gland from returning to its normal position. Inflammation and hypertrophy of the gland account for its red, swollen appearance at the medial canthus of the eye.

If a veterinarian examines the Pet soon after prolapse, it is possible that the

prolapsed gland will not have significantly hypertrophied, and the veterinarian can reduce and reposition the gland appropriately behind the third eyelid. The gland may also reduce spontaneously or even undergo cycles of prolapse and reduction. However, even reducing the gland in a timely manner does not solve the underlying anatomical problem. Once prolapse of the third eyelid gland occurs, the patient will most likely suffer a nonreducible prolapse in the future; to fully solve the problem, surgical intervention is required.

Prolapse of the third eyelid gland is not a life-threatening condition; many patients endure it for months or even years before receiving the proper treatment. However, the inflamed, sensitive tissues of the gland and conjunctiva are likely to cause Pets a great deal of discomfort. In addition, Pets with untreated, prolapsed third eyelid glands have a greater risk of developing ophthalmic conditions such as chronic conjunctivitis, ocular discharge and keratoconjunctivitis sicca (KCS).<sup>1</sup> As advocates for Pets, it is our role—and our duty—to inform clients of their Pets' discomfort and potential risks, and to recommend timely and appropriate treatment.

In addition to worrying about their Pets' health, clients may also be concerned about cosmetic issues because the hypertrophied gland is a prominent and unsightly feature affecting a Pets' appearance. While cosmetic issues may be less pressing from a clinical standpoint, cosmetic appearance can motivate clients when a veterinarian recommends treatment for Pets with cherry eye.

### Treatment of prolapse

Traditionally, one of the main treatments for a prolapsed gland had been to excise the gland. Thankfully, with an increased under-

standing of the importance of the third eyelid gland, as well as the advent of multiple surgical techniques for surgical repositioning of the gland, excision is no longer the treatment of choice.<sup>1</sup>

Because the third eyelid gland contributes approximately 40 percent of the tear production needed by the eye,<sup>2</sup> it plays an essential role in maintaining the aqueous tear film that protects the cornea. Removing this gland places the Pet at increased risk of developing KCS,<sup>1</sup> also known as *dry eye*, a condition in which the eye does not produce enough tears to effectively lubricate and protect the cornea from scratches, irritation and desiccation. The main concern in most cases is that the lacrimal gland might lose full function (*e.g.*, because of immune-mediated issues), leaving the eye unable to produce enough tears to develop a complete and fully protective tear film.

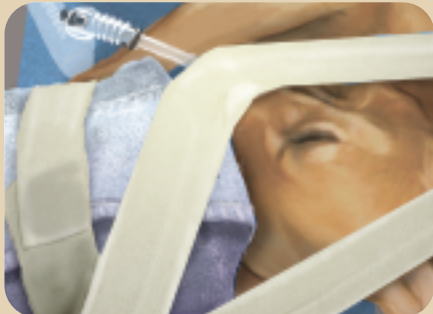This concern is made all the more serious because many breeds that are most susceptible to a prolapse of the third eyelid gland are also more susceptible to KCS.<sup>1</sup> This is clinically important because KCS is an incurable condition that requires daily doses of supplemental lubricants as well as expensive lacrimogenic drugs, such as cyclosporine, for the rest of an afflicted Pet's life. This incurs considerable expense for the client and requires a large expenditure of effort. Moreover, if the client does not administer treatment consistently the Pet will be subjected to considerable pain and discomfort. So, to avoid risking insufficient

Figure 1: Appearance of third eyelid gland prolapse



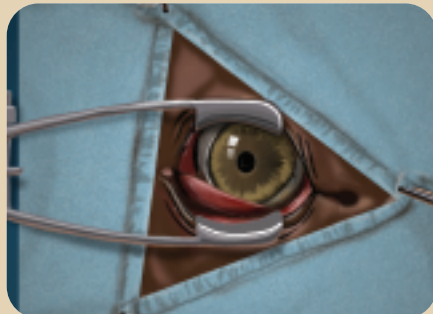Note the everted eyelid and the red, swollen appearance of the gland.

**Figure 2: Positioning for the procedure**



The patient's head is positioned with towels to elevate the nose and keep the eye parallel to the table. White tape should be placed across the muzzle and at the base of the ear to hold the head in position. The tape should be kept clear of the surgical area.

**Figure 3: Preparing the surgical area**



Drapes are placed in a triangular pattern around the eye and held in place with towel clamps. An eyelid speculum is used to hold the upper and lower eyelids open for surgery.

tear production and the development of KCS, excision of the third eyelid gland should be avoided.

Multiple gland-sparing techniques can provide positive results in the vast majority of cases, so third eyelid gland removal is no longer a standard practice in the veterinary profession. Some methods include suturing the gland to the globe inferiorly and suturing the gland to the periosteum of the inferior orbital margin.<sup>1</sup> However, both these techniques involve difficult, lengthy procedures, which decrease their success. One of the most useful techniques is the modified Morgan pocket technique outlined below, which provides positive results and low recurrence rates.

### Presurgical considerations

Sometimes the gland may become extremely inflamed or even infected. In those cases, it may be appropriate to initiate treatment with topical antibiotics and corticosteroids for five to seven days to reduce hypertrophy of the gland and make the surgery easier to perform. Because corticosteroids may delay healing, it is advisable to wait at least a week after the cessation of steroid treat-

ment before performing surgery on the gland. Using antibiotics or antibiotics plus steroids will not, however, permanently remedy glandular hypertrophy.

### Instrumentation and surgical preparation

The instrumentation for the modified Morgan pocket technique is fairly simple and can be customized according to the surgeon's preference.

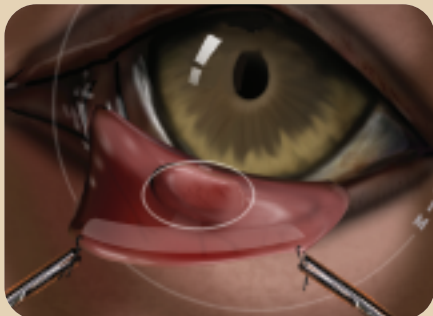
Use a delicate pair of forceps to position the globe and manipulate the conjunctiva. While the standard Adson or Brown-Adson tissue forceps are unlikely to damage the conjunctiva, they are usually too large, and Bishop-Harmon forceps are preferable.

Likewise, you should use 5-0 or smaller Vicryl™ (Ethicon) sutures for the delicate work of suturing the third eyelid. Vicryl is a superior option for conjunctival surgery because PDS™ and Monocryl™ (Ethicon) sutures may cause corneal or conjunctival irritation, and they dissolve more slowly. Using suture sizes of 5-0 and smaller can be challenging if you are not accustomed to this small size; it can easily become tangled in the surgical instruments. However, familiarity with this delicate suture material will come with practice.

The surgical preparation is relatively minimal because the entire procedure takes place within the patient's eyelids. Nonetheless, perform standard sterile surgical preparation for ophthalmic surgery, including shaving the area around the orbital fissure to create a sterile area. Chlorhexidine should not be used inside the eyelids because of irritation and damage to the delicate tissues;<sup>3</sup> instead, use a sterile saline solution to flush the eye.

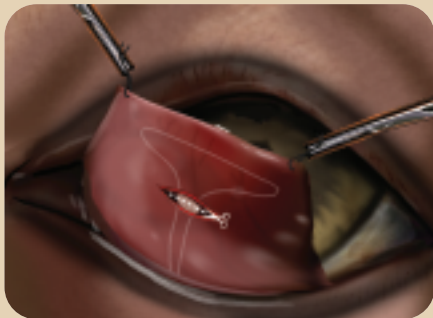*Figure 2* depicts a canine patient in the early stages of positioning for the procedure.

**Figure 4: Positioning the third eyelid for surgery**



Note that the third eyelid is exteriorized and everted so that its bulbar (interior) surface is exposed. The third eyelid is held in place using the stay sutures at both the lateral and medial edges of the free margin. Note the position of the T-shaped cartilage of the third eyelid (outlined area). The cartilage will not be visualized this easily during the surgery but can be palpated to ascertain whether it has been bent.

**Figure 5: Correcting bent cartilage**



Place the third eyelid over the eye so that the palpebral side is exposed, and determine via palpation where the curvature of the cartilage is the greatest. Incise the palpebral conjunctiva to expose the cartilage at the site of the bend, undermine the cartilage to free it from the bulbar conjunctiva and incise the cartilage itself. Preferably, this should be done with Stevens tenotomy scissors to prevent trauma to the surrounding tissues. Then, close your incision and proceed with the third eyelid gland prolapse repair.

In *Figure 3*, the surgical area is draped in a triangular pattern to give good exposure to the eye while covering the remainder of the head. An eyelid speculum should be placed to keep the eyelids open.

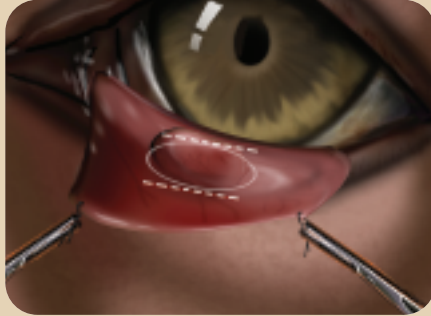Place surgical stay sutures in the third eyelid free margin so it can be manipulated during the procedure. The stay sutures pass through the third eyelid only and provide handles for manipulating the eyelid. Generally, place only one stay suture at each edge of the free margin (medially and laterally); it is important, however, not to place the sutures between the free margin and cartilage of the third eyelid. This procedure allows for good mobilization of the third eyelid; one effective technique is to hold the stay sutures with mosquito hemostats, which are heavy enough to hold the lid in place without damaging it. *Figure 4* depicts the proper placement of the stay sutures and hemostats.

### **Modified Morgan pocket technique**

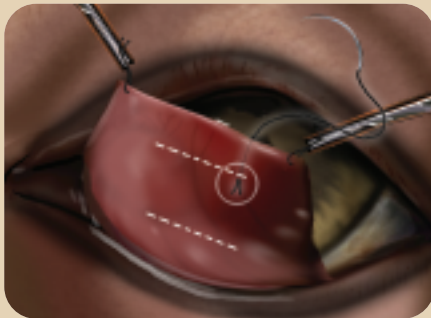
Once the surgical preparations are complete, determine the status of the T-shaped cartilage within the third eyelid via palpation. Bending of the T-shaped cartilage within the third eyelid is a clinically important complication that can threaten the success of the surgery. If the prolapse has been present for a long period of time, the cartilage tends to remain bent in the twisted shape it held when the gland was prolapsed. This is similar to the way a tightly rolled-up piece of paper curls back onto itself even after it is pushed flat. After surgical correction of the prolapsed gland, the bent cartilage is likely to return to its previous bent position and place constant pressure on the gland to pull away from the anchors holding it in place.

In order to reduce the probability of recurrence, correct this complication, if present, before performing the third eyelid

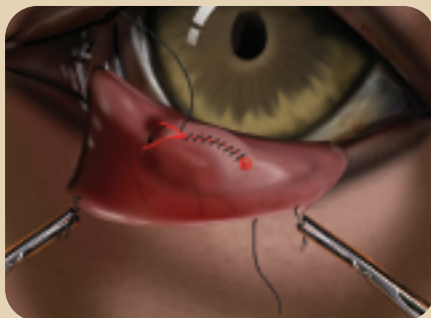**Figure 6: Modified Morgan pocket technique**



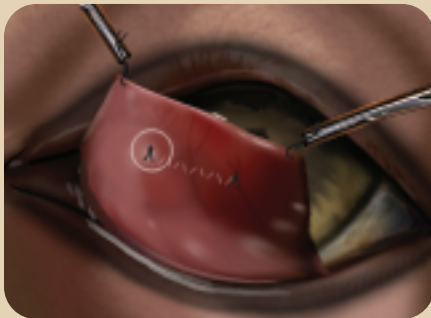**6A:** Preparing a pocket. Make two superficial curvilinear incisions parallel to the free margin on the bulbar side of the third eyelid, one on each side of the prolapsed gland. Make sure, however, not to cut all the way through the eyelid. The incisions should extend the entire width of the third eyelid gland, and the two incisions should not be allowed to intersect each other.



**6B:** Attaching the sutures. Fold the eyelid over the eye so the palpebral (outer) side of the eyelid is exposed. Using 5-0 or smaller Vicryl suture, anchor the initial knot to the palpebral side of the third eyelid so that it will be directly opposite to the end of one of the bulbar incisions. Anchoring on the external side of the eyelid is necessary to avoid abrasion of the cornea by the suture ends. The suture can then be passed through the third eyelid to the bulbar side at the end of one of the incisions.



**6C:** Making a pocket. Fold the eyelid outward again so you are able to work with the bulbar side. Starting from the exit point of your suture at the end of one of your two incisions, begin to suture the two incisions together using a simple continuous pattern. The tissue at the juncture of the two incisions will behave in manner similar to debrided conjunctival epithelium and will heal together around the gland. Be sure to leave an opening at each of the two ends of your pocket to provide an egress for tears to flow out of the gland. The egress will remain open if the incisions are parallel and the suture bites do not extend beyond the width of the incision.



**6D:** Tightening the pocket. When you finish your closure of the two sides of the pocket, pass the suture again from the bulbar to the palpebral side of the third eyelid and fold the eyelid over so the palpebral side is again visible. Pull the suture tight from the external side, and anchor it again on the palpebral side so that the knot cannot abrade the cornea.

gland repair. This can be done by clipping the cartilage at the point of the bend so that it can be effectively straightened (*Figure 5*, page 39). Once this short procedure is completed, proceed with the remainder of the third eyelid gland repair.

In the modified Morgan pocket technique, the surgeon creates a tunnel of tissue to surround the prolapsed gland and holds it in its proper place behind the eyelid. *Figures 6A through D* (page 40) depict the steps in this procedure.

Once you complete the initial suturing procedure, it will be necessary to repeat the suturing pattern to minimize the chance of recurrence. It won't be necessary to make new incisions, but the suture should again be anchored on the palpebral side of the eyelid and passed through to the bulbar side. Repeat the same procedure for suturing depicted in *Figures 6B through D*, except this time, oversew the original simple continuous suture pattern with a pattern of simple continuous *mildly inverting* sutures. The purpose of this is to close any gaps that may be left in the original pattern and to bring the two incisions closer. The suture pattern should be tied off on the palpebral side of the third eyelid. Again, make sure there is an area of egress for the tears to flow through.

### **Postoperative care**

Following surgery, give the patient appropriate oral, nonsteroidal anti-inflammatory drugs and treat the eye with a topical ophthalmic antibiotic ointment three times daily. It is important not to use topical corticosteroids postoperatively, as this can delay healing and lead to an increased incidence of prolapse recurrence.

You should ensure that the patient cannot scratch the eye after surgery. An Elizabethan collar is required to protect the

surgical site, and you may wish to bandage the Pet's paws and nails. During recovery, the eye is likely to be irritated because of surgical manipulations, and if the site is not protected, the patient is likely to scratch the eye and traumatize the surgery site.

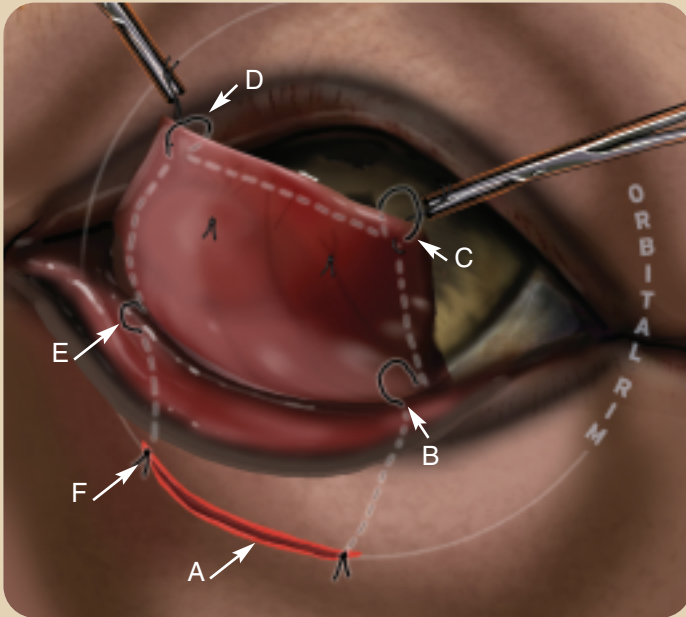
It may be beneficial to recheck the eye 24 hours after sending the patient home, if possible, or to call the client the next day to check on the patient's condition and the client's ability to properly medicate the eye. The client should also be warned that the eye will likely appear a bit more inflamed before it begins to improve; frequently, the third eyelid gland will appear as a large swelling behind an elevated third eyelid. This swelling will subside eventually because the gland is now covered by healthy conjunctiva and has been restored to a more vascularly normal position. The swelling can take weeks to reduce completely.

### **Management of recurrence**

Along with its technical ease, low patient risk and short anesthesia time, the pocket technique has a low rate of recurrence. The original reported recurrence rate for the procedure was 10 to 20 percent,<sup>4</sup> and lower rates of less than 10 percent have been reported anecdotally.<sup>5,6</sup> Some breeds predisposed to the condition, such as English Bulldogs and large breeds such as Mastiffs, may have a higher rate of recurrence. The recurrence rate may be minimized by oversewing the closure as directed above, and by ensuring that the T-shaped cartilage is not bent. If the prolapse recurs, it will be necessary to repeat the pocket procedure.

To ensure that the third eyelid gland does not again prolapse, in some cases an additional tacking procedure should be performed. The purpose is to tack the third eyelid—but not the gland itself, which

**Figure 7: Tacking the third eyelid after recurrence**



Palpate the ventral orbital rim through the skin ventral to the inferior eyelid, and make a small incision equal in length to the width of the third eyelid (A) directly over the orbital rim to expose the periosteum. Using 3-0 PDS suture, anchor the suture to the periosteum at the lateral aspect of the incision, then run the suture under the skin to exit laterally under the lower lid at the base of the third eyelid (B). Run the suture through the inner tissue of the third eyelid along its lateral edge, and exit at the lateral aspect of the free margin (C). Loop the suture around to re-enter the third eyelid at the bulbar side, and run the suture through the third eyelid tissue along the free margin to exit at the medial aspect (D). Again, loop around to re-enter the tissue at the medial aspect of the free margin, run the suture along the medial edge of the third eyelid and exit medially at the base of the third eyelid under the lower lid (E). Next, run the suture under the lower lid to exit at the medial aspect of the skin incision (F). When the suture is pulled tight, the third eyelid will slide under the inferior eyelid margin. Anchor the suture to the periosteum. When this is completed satisfactorily, the skin incision can be closed in a routine fashion.

should already be well-positioned within the eyelid—to the periosteum of the orbital rim by running a suture along all three margins of the third eyelid and then through the skin ventral to the lower lid (Figure 7). Avoid tacking the gland itself as it may damage the gland, leading to long-term atrophy and complete loss of function.

## Expected outcomes

The pocket technique (and, potentially, tacking procedure) provides a good prognosis for permanent repair of prolapsed third eyelid glands. This procedure alleviates the pain and discomfort Pets with this condition suffer and also helps to avoid potential ill effects, such as reduced tear production. By telling clients how important this procedure is to the well-being of Pets afflicted with cherry eye, you can help fulfill your role as an advocate for Pets. The technique is simple to perform and carries a greater success rate with fewer complications than other surgical options. It is an ideal procedure for general practitioners to perform and a good early point to increase our comfort levels with similar ophthalmic procedures. 🐾

## References

1. Slatter DS, ed. *Fundamentals of veterinary ophthalmology*. 3rd ed. Philadelphia, Pa: WB Saunders Co, 2001, 237-259.
2. Saito A, Izumisawa Y, Yamashita K, et al. The effect of third eyelid gland removal on the ocular surface of dogs. *Vet Ophthalmol* 2001;4:13-18.
3. Hamill MB, Osato MS, Wilhelmus KR. Experimental evaluation of chlorhexidine gluconate for ocular antisepsis. *Antimicrob Agents Chemother* 1984;26:793-796.
4. Morgan RV, Duddy JM, McClurg K. Prolapse of the gland of the third eyelid in dogs: A retrospective study of 89 cases (1980-1990). *J Am Anim Hosp Assoc* 1993;29:56.
5. Cherry eye. Northwest Animal Eye Specialists Web site. Available at: <http://www.peteyedoctor.com/620642.html>. Accessed May 31, 2007.
6. Stengard M. Cherry eye—dry eye. *Pet Tribune* [on-line]. September 2001. Available at: [http://www.dachshund.org/health\\_cherry\\_eye.html](http://www.dachshund.org/health_cherry_eye.html). Accessed May 31, 2007.

**Ari Zabell, DVM, DABVP (canine/feline)**, is a senior medical director for Banfield, The Pet Hospital, overseeing veterinarians in California, Oregon, Washington and northern Nevada. He was as a practitioner in Reno, Nev., before joining VetSmart in Federal Way, Wash., as hospital director and later chief of staff before becoming a field director for western Washington.